

A Case Report of a Rare and Unusually Large Thymus Gland and its Comprehensive Review

Dr. Uma B. Gopal¹, Dr. Surendra Chaudhary², Dr. Daiarisa Rymbai³

¹Professor, ^{2,3}PG Scholars, Department of Rachana Sharir, Sri Dharmasthala Manjunatheshwara College of Ayurveda and Hospital
Hassan, Karnataka.

Abstract

Thymus gland is a central lymphatic organ that lies in the superior and anterior mediastinum. It shows a unique morphological change over time in its size, shape and density according to age. Its size increases with age and attains maximum at the age of puberty and thereafter it undergoes involution converting into the fibro-fatty tissue. Abnormally large sized Thymus gland is uncommon variation in adults and is usually found in newborns and young children. We found an abnormally large sized Thymus gland in a 66 years old male cadaver during routine PG dissection at Department of Rachana Sharir, Sri Dharmasthala Manjunatheshwara College of Ayurveda and Hospital, Hassan, Karnataka, India. Persistent Thymus gland or its hyperplasia in adult may be associated with clinical conditions like Myasthenia gravis, compression of trachea, oesophagus and veins of the neck. This fact is clinically important for the radiologists, surgeons, physicians in differential diagnosis of mediastinal mass, thoracic surgeries and management of Thymus related pathologies.

Key words: Thymus gland, hyperplasia, lymphatic system, mediastinal mass.

Introduction

Thymus gland is a primary lymphoid organ situated in the superior and anterior mediastinum. It is an endocrine gland that secretes the peptide hormones including thymopoietin and thymosin which appear to be essential for the normal development of T lymphocytes and immune response. It extends inferiorly to the level of 4th costal cartilage and superiorly to the neck or sometimes it may extend to the lower border of thyroid gland or even higher. It lies posterior to the sternum, adjacent parts of upper four costal cartilages, sternohyoid and sternothyroid muscles and anterior to the pericardium, aortic arch with its branches, left brachiocephalic vein and trachea^{1,2,3}.

Case Report

We report an unusually large sized thymus gland in a 66 years old male cadaver

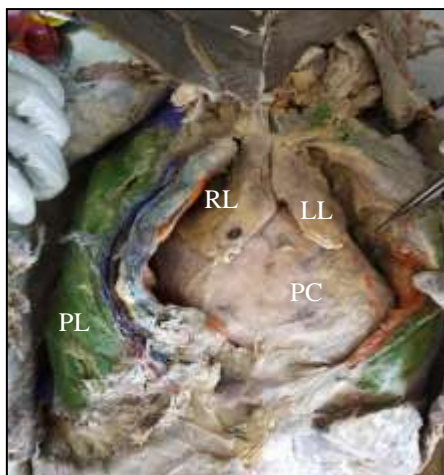


Figure 1: Thymus in situ.
RL- Right lobe, LL- Left lobe,
PC- Pericardium, PL- Pleura

with moderate built during routine PG dissection of thoracic region at Department of Rachana Sharir, Sri Dharmasthala Manjunatheshwara College of Ayurveda and Hospital, Hassan, Karnataka, India. It was the first case of variation in size of Thymus gland we found among 30 cadavers dissected at our department since 2011.

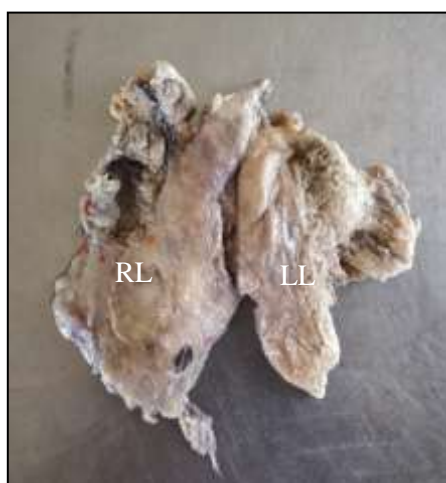

Figure 2:Thymus- Anterior view
RL-Right lobe, LL- Left lobe

The thymus is located in the superior-anterior mediastinum behind the manubrium sterni and in front of the pericardium, arch of aorta and brachiocephalic veins. It was 7cm long at the midline where its two lobes were fused together and its width

was 12cm at its mid horizontal plane. The right lobe was larger measuring 10×5.5cm whereas left lobe was 10×6.5cm in size. Weight of the present specimen was 45gms and thickness was 1.5cm at middle of the both lobes. Impression of upper border of manubrium sterni was visible on its upper anterior surface and its upper right border was extending in the neck region anterior to the trachea. Impressions of right atrium, superior venacava and right brachiocephalic vein were clearly visible on the posterior surface of right lobe and that of aortic arch on the posterior surface of left lobe. A large branch from internal thoracic artery was supplying to thymus. A larger vein was observed draining to left brachiocephalic vein and a small vein was accompanying the branch of internal thoracic artery. We could not able to find the nerve supplying the thymus; it might have damaged during dissection.

Discussion

Anatomical Implication of Thymus gland

Thymus is a soft, bilobed structure which acts as a central organ of lymphatic system. It consists of two pyramidal lobes connected with each other across the midline by fibro-areolar tissue. The right lobe is larger than the left one. Each lobe is covered by a connective tissue capsule and the septa passing inwards from the capsule incompletely divides




Figure 3: Thymus-Posterior view
AA- Impression for aortic arch
BC- Impression for right
brachiocephalic vein

each lobe into a large number of lobules. It demonstrates unique developmental changes over the time, and therefore it is difficult to define the structure and determine the weight of the thymus appropriate for age. It is relatively large at birth, progressively increases in size and weight up to the age of puberty. It attains maximum absolute weight at 15 years of age, then subsequently undergoes involution. During involution, the epithelial component atrophies, resulting in scattered small lymphocytes in abundant fibro-fatty tissue. By old age it has been almost replaced entirely by fibrous and fatty tissue and is difficult to distinguish from surrounding connective tissue. Average weight of thymus at birth is 10-15gms, at puberty 20-30gms and at mid adult life 10gms.

Thymus is fed by branches from Internal thoracic and Inferior thyroid arteries and venous blood from it is drained into the Left Brachiocephalic, Internal thoracic and Inferior thyroid veins. Vasomotor nerves from stellate ganglion supply the gland while its capsule is innervated by phrenic nerve and descendens cervicalis. It does not receive any lymph vessels, but gives off efferent vessels.^{4,5}

Anatomical aspects such as location, shape, and size of the normal thymus is important for differentiation of the thymus from other mediastinal structures, such as lymph nodes or the superior sinus of the pericardium. The size of a normal thymus has been extensively studied by different authors.

Baron et al analyzed 154 mediastinal CT scans and reported that the mean thickness of a normal thymus decreased with advancing age from 1.1 cm (standard deviation, 0.4 cm) for the 6–19 year age group to 0.5 cm (standard deviation, 0.27 cm) for patients over age 50 years. The maximum thickness was 1.8 cm in patients under 20 years and 1.3 cm in patients over 20 years of age.⁶

In present study, the thymus we found was unusually large with respect to the age of the cadaver. Its length in the mid line at the connection of two lobes was 7cm and maximum width was 12cm. The right lobe was larger measuring 10cm and 5.5cm in length and width respectively whereas the length and width of left lobe was 8cm and 6.5cm. It was 1.5cm thick and 45gms in weight. However, error in measurement of weight will be there as the cadaver was fixed in formalin. This case was one of rare variant with respect to age of cadaver as the thymus is actively functioning in pre-adults, the majority of the previously reported cases occurred in neonates, infants, and older children, typically under the age of 15 years.

Embryological Implication of Thymus gland

The Thymus arises bilaterally from the endoderm of ventral tubular parts (Thymic rudiment) of third pharyngeal pouches. In early development, the pouch is cut off both from the pharyngeal wall and surface ectoderm. The thymic rudiment is soon

differentiated into thinner cranial and broader cranial segments. The cervical part of thymus is derived from the cranial segments while the broader segments of both sides enter the thorax and develop into two lobes of the thymus. The two lobes are united to each other by connective tissue. The endodermal cells of thymus are invaded by vascular mesoderm containing numerous lymphoblasts. The invading mesenchyme partially breaks up the thymic tissue into isolated masses and thus it appears as lobulated. Fragmentation of the cervical part of thymus may give rise to accessory thymic tissue present in relation to the superior parathyroid glands and is believed to be derived from the fourth pharyngeal pouch.⁷

Development of thymus begins in the 6th gestational week. Migration of tissue occurs during the 8th week, leading to a fusion of the bilateral lobes, with the thymus occupying its final position in the antero-superior mediastinum. In the course of its development, until the 9th gestational week, the thymus remains purely epithelial. By the 10th week, small lymphoid cells migrate from fetal liver and bone marrow, leading to lobulation of the gland. Further differentiation into cortex and medulla is completed by 14–16 weeks. Thereafter, the thymus grows rapidly and attains its greatest weight of average, 15gms in relation to body weight before birth.⁸

The thymus migrates from the third and fourth branchial pouches to the anterior mediastinum during its course of development, so ectopic thymic tissue or ectopic thymoma can occur anywhere along this pathway. It may manifest as a neck mass that are encountered on computed tomography or magnetic resonance imaging. Thus, knowledge of the embryologic features of the thymus is important in recognizing these entities.⁸

Histological Implication of Thymus gland

A basic knowledge of the histological features of the thymus is essential for understanding the various pathological conditions that affect this gland, including thymic epithelial tumors. Each lobe of thymus has a fibrous capsule which projects in the substance of the organ as incomplete trabecular septa dividing the lobes into numerous lobules. Each lobule is about 2mm in diameter. The blood vessels are conveyed to the inner substance through the trabecular septa. Each lobule consists of outer cortex and inner medulla. The medulla of adjoining lobule is continuous.

The cortex and medulla contain cells of two distinct lineages. These cells are of four types- Epitheliocytes, Thymocytes, Macrophages and Hassall's corpuscles. The cortex is composed primarily of thymocytes (T lymphocyte), with a few epithelial and mesenchymal cells, whereas the medulla is composed of more epithelial cells but fewer lymphocytes.

The epitheliocytes derived from the endoderm lining the pharyngeal wall form a continuous sheet which lines the inner surface of the fibrous capsule, trabecular septa and around the blood vessels at the cortico-medullary junction. The deeper cells in the lobule develop processes and are connected to similar one forming the reticulum. This sheet of epitheliocytes form an effective haemo-thymic barrier which from outside inwards consists of -

- (a) a layer of continuous endothelial cells of capillaries;
- (b) a thick basement membrane;
- (c) a tissue space which occasionally contains tissue fluid,
- (d) a continuous layer of reticular epithelial cells.

The barrier is impermeable to antigens but the nutritive substances and stem cells from the bone marrow can pass to the thymus through it. Cortical epitheliocytes are also described as thymic nurse cells which destroy lymphocytes that react against self antigens.

Lymphocytes of the Thymus or Thymocytes are densely packed in the cortex and found less abundantly in the medulla. Stem cells formed in bone marrow travel to the thymus and come to lie in the superficial part of the cortex, and divide repeatedly to form small T lymphocytes. As these thymocytes divide they pass deeper into the cortex, and into the medulla. Ultimately, they leave the thymus by passing into blood vessels and lymphatics. A fair number of macrophages are found in the thymus, placed subjacent to the capsule, at the corticomedullary junction, and in the medulla. The subcapsular macrophages are highly phagocytic. Deeper lying macrophages are dendritic cells^{4,9}.

Corpuscles of Hassall are small rounded structures present in the medulla of the thymus. Each corpuscle has a central core formed by epithelial cells that have undergone degeneration. Around this mass there is a wall formed by concentrically arranged epithelial cells. The central mass of the corpuscle may also contain degenerating macrophages. The functional significance of the corpuscles of Hassall is not clear, however it is known that they are the potent source of cytokine Thymic Stromal Lymphopoietin (TSLP) which directs the maturation of dendritic cells, and increase the ability of dendritic cells to convert thymocytes to a regulatory T cell lineage. Researchers have found tissue specific self-antigens in Hassall's corpuscles and revealed their role in the pathogenesis of diseases like rheumatoid arthritis, multiple sclerosis,

autoimmune thyroiditis, Good pasture's syndrome and others¹⁰.

Pathophysiological Implication of Thymus gland

The thymus is one of the central lymphoid organs and plays an important role in cellular immunity by generating circulating T lymphocytes. Although the need for the thymus to generate a continuous supply of T cells decreases with advancing age, the thymus continues to serve as the site of T-cell differentiation and maturation throughout life¹¹.

The lymphocytes in the thymus are derived from the stem cells of the bone-marrow. The lymphocytes proliferate repeatedly by mitosis in an antigen-free environment, and populate more thickly in the cortex than the medulla. About 90% of the thymic lymphocytes are destroyed within 3 to 5 days probably due to the fact that these cells become auto-allergen to one another or to the host. The degenerated lymphocytes are phagocytosed by the macrophages. About 5% of the surviving lymphocytes appear in the circulating pool through the haemo-thymic barrier as uncommitted immunologically competent cells and appear in the primary lymphatic follicles of lymph nodes and spleen. About 75% of the circulating lymphocytes of blood are derived from T-lymphocytes¹¹.

The T-cells are concerned with cell-mediated immunity, homograft rejection and occasional delayed hypersensitivity reaction. Uncommitted lymphocytes react to varieties of new antigens by liberating specific lymphokines. The T-cells play major roles in counter-acting viruses, tubercle bacilli, salmonellae and various fungal infections⁴.

The proliferation of T-lymphocytes and their conversion into cells capable of reacting to antigens

takes place under the influence of hormones produced by epithelial cells of the thymus. T-lymphocytes are influenced by direct cell contact with epitheliocytes. Hormones produced by the thymus may also influence lymphopoiesis in peripheral lymphoid organs. This influence appears to be especially important in early life, as lymphoid tissue do not develop normally if the thymus is removed. Thymectomy has much less influence after puberty as the lymphoid tissues have fully developed by then. A number of hormones produced by the thymus have been identified.

Thymulin- enhances the function of various types of T-cells, especially that of suppressor cells.

Thymopoietin- stimulates the production of cytotoxic T-cells. The combined action of thymulin and thymopoietin allows precise balance of the activity of cytotoxic and suppressor cells.

Thymosin alpha 1- stimulates lymphocyte production, and also the production of antibodies.

Thymosin beta 4- is produced by mononuclear phagocytes. it promotes migration of cells, formation of blood vessels, maturation of stem cells, survival of various cell types and lowering of the production of proinflammatory cytokines.

Thymic humoral factor- controls the multiplication of helper and suppressor T-cells.

The hormones or other hormone like substances produced in the thymus also influence the adenohiphysis and the ovaries. The activity of the thymus is also influenced by hormones produced by the adenohiphysis, adrenal cortex and sex hormones.⁹

Clinical Implication of Thymus gland

Anterior mediastinal masses are one of the confusing pathological conditions encountered in the medical practice. Thymic hyperplasia is extremely rare among adults though it is very common in infants¹³. Recognition of a normal thymus in adults is significantly important because it can be misdiagnosed as an anterior mediastinal lesion on screening CT images, usually performed in middle aged and older patients. The differential diagnosis in adults must take into consideration with thymoma, lymphoma, teratoma, and benign thyroid tumors.^{1,14}

Thymic hyperplasia histologically is of two distinct types: true thymic hyperplasia and lymphoid hyperplasia. These both types are associated with different groups of pathologic conditions and manifest as diffuse symmetric enlargement of the thymus, so that it is difficult to distinguish between the two types on the basis of imaging findings alone. Diffuse symmetric enlargement of the gland is the key morphologic feature of hyperplasia, whereas neoplasm tends to manifest as a focal mass, as in thymoma¹⁴

The Thymus is enlarged beyond the upper limit of normal for a given age but structural architecture remains normally organized in case of True thymic hyperplasia. This disease entity is seen when a patient is recovering from some recent stress such as chemotherapy for neoplasm, corticosteroid therapy, irradiation, or thermal burns. Under such conditions, the thymus may respond by becoming atrophic; however, it grows back to its original size after cessation of the stress. The thymus sometimes grows to an even larger size after such stress, a phenomenon known as rebound hyperplasia.^{11,14}

Choyke et al in a study in 29 patients noted that 25% of patients developed rebound hyperplasia in several

months (range, 3–8 months; mean, 4.2 months) after cessation of chemotherapy¹⁵.

Lymphoid hyperplasia of the thymus refers to the presence of an increased number of lymphoid follicles.¹⁴ This condition is most commonly associated with *Myasthenia gravis*, being seen in up to 65% of cases. *Myasthenia gravis* affects one-third to one-half of all thymoma patients.¹⁶

In spite of the frequent association between thymoma and myasthenia gravis, the mechanism of the association is not fully understood. However, it is known that myasthenia gravis is an autoimmune disease affecting the nicotinic acetylcholine receptor at the neuromuscular junction, and production of auto antibodies against the acetylcholine receptor sub-unit is assumed to cause myasthenia gravis.¹⁷

The source of acetylcholine receptors in the thymus is considered to be myoid cells, which are in very close contact with antigen-presenting interdigitating cells. Thymectomy improves myasthenia gravis in some patients regardless of whether thymoma is present or not. Lymphoid hyperplasia of the thymus is observed in a number of immunologically mediated disorders, including SLE, rheumatoid arthritis, scleroderma, vasculitis, thyrotoxicosis, and Graves disease, pure red cell aplasia, hypogammaglobulinemia, and non thymic cancers but are less frequently occurring than Myasthenia gravis⁸.

In a study by Ackman et al. which investigated 20 to 30-year-old patients, males showed more rapid fatty intercalation than females. These findings suggest that the onset of thymic involution in women is delayed by approximately 10–20 years in comparison to men. Thymic involution is completed by the age of

60 years in men and 70 years in women, and the sex difference in the thymic appearance seems to eventually fade away by the age of 70 years. Sex steroids are considered to be an important factor for the sex difference of the thymus.¹⁸

The amount of fat tissue in the anterior mediastinum is also associated with BMI and could affect the appearance of the thymus, and there is a known suppressive effect of cigarette smoking on the immune system.¹

Araki T et al. carried out a study involving total 2540; 49% male and 51% female healthy individuals with a mean age of 58.9 years by evaluating the CT appearance of thymic glands with four-point scores (according to the ratio of fat and soft tissue), size and morphology. These were correlated with participants' age, sex, BMI and smoking history. They found complete fatty replacement of the thymus in 74 %, predominantly fatty attenuation in 18 %, half fatty and half soft-tissue attenuation in 7 %, and solid thymic gland with predominantly soft-tissue attenuation in 1 %. Female participants from 40-69 years of age showed thymic glands with less fatty degeneration than male. The result also revealed that thymic scores were associated with smoking status and BMI. Participants with a fatty degenerated thymus are more likely to be former smokers (49 %). On the other hand, those with a solid thymus were more likely to have no primary exposure to cigarette smoking (64 %). Participants with higher BMI showed thymic glands with higher fatty degeneration.¹

Pharmacological Implication of Thymus gland

The thymus gland is essential in early weeks of neonatal life and it regulates the growth of peripheral lymphoid tissues. The growth hormones of the anterior pituitary and thyroid hormones stimulate the thymus to grow before attaining puberty. The steroid hormones from the adrenal cortex and from the gonads favor the involution of the thymus, which is commonly observed in post-pubertal life. Cortisone administration to the newborn is detrimental, because it hinders the normal immunological response by reducing the lymphocytes in the thymus⁴. However, the thymus may regrow when corticosteroids are discontinued suggesting that corticosteroid effects are temporary and reversible as seen in different radiological and animal studies.¹⁹

Conclusion

Thymus gland is a primary lymphatic structure which plays a predominant role in bodily immune mechanism by generating the circulating T lymphocytes. It shows unique structural changes according to the age, so differentiation of a normal thymus from thymic lesions can sometimes be problematic for radiologists and surgeons. Knowledge of the embryological, histological, and normal morphologic features, normal variations and ectopic locations of thymus and its dynamic changes is essential for comprehensive understanding of the normal thymus and thymic diseases. Familiarity with the same is necessary to radiologist, surgeons, physicians and academicians to contribute in diagnosis and effective clinical treatment of affected patients.

References

1. Araki T, Nishino M, Gao W, Dupuis J, Hunninghake GM, Murakami T, Washko GR, George T, O'Connor, Hatabu H. Normal thymus in adults: appearance on CT and associations with age, sex, BMI and smoking Eur Radiol DOI 10.1007/s00330-015-3796-y
2. Henry G. Gray's anatomy (2005)- Anatomical basis of clinical practices. edited by Standring Susan; ed 39th., Elsevier Churchill, Livingstone: P 1423.,
3. Marieb E. Human Anatomy and Physiology. 4th ed. California: Benjamin/Cummings Science Publishing; 1998:618)
4. Datta AK. Essentials of Human Anatomy. 6th ed. Kolkata: Current Books International; 2017, Vol 2:p140.
5. Chaurasia BD. BD Chaurasia's Human Anatomy. edited by Garg K. 7th ed, New Delhi :CBS Publishers and Distributors; Reprint 2017, Vol 3: p151.
6. Baron RL, Lee JK, Sagel SS, Peterson RR. Computed tomography of the normal thymus. Radiology. 1982; 142: 121–5.
7. Singh I. Human Embryology. 10th ed. New Delhi: The Health Science Publisher; Reprint 2015,p100.)
8. Nishino M, Ashiku S.K., Kocher O.N., Thurer R. L., Boisselle P.M., Hatabu H. The Thymus: A Comprehensive Review. RadioGraphics 2006; 26:335–348 .Published online 10.1148/rg.262045213.
9. Singh I. Textbook of Human Histology. revised and edited by Neelam Vasudeva and Sabita

- Mishra. 8th ed. New Delhi: The Health Science Publisher;2016: p102
10. Watanabe N, Wang Y, Lee H, Ito T, Wang Y, Cao W. Liu Y. Hassall's Corpuscles instruct dendritic cells to induce CD4+CD25+regulatory T cells in human thymus. *Nature*. 2005; 436(7054):1181-5.
 11. Shimosato Y, Mukai K. Tumors of the thymus and related lesions. In: Shimosato Y, Mukai K, eds. *Atlas of tumor pathology: tumors of the mediastinum*, fasc 21, ser 3. Washington, DC: Armed Forces Institute of Pathology, 1997; 158–168.
 12. Lamesch A.J., Massive thymic hyperplasia in infants., *Z. Kinderchir.* 38 (1983) 16–18. doi:10.1055/s-2008-1059932.
 13. Gonzalez M., Ris H.B., Krueger T., Jayet P.Y., Management of anterior mediastinal masses in adults. *Rev. Mal. Respir.* 29 (2012) 138–148. doi:10.1016/j.rmr.2011.11.015.
 14. Mendelson D.S. Imaging of the thymus. *Chest Surg Clin N Am* 2001;11:269–293.
 15. Choyke PL, Zeman RK, Gootenberg JE, Greenberg JN, Hoffer F, Frank JA. Thymic atrophy and regrowth in response to chemotherapy: CT evaluation. *AJR Am J Roentgenol* 1987;149:269–272.
 16. Lewis JE, Wick MR, Scheithauer BW, Bernatz PE, Taylor WF. Thymoma: a clinicopathologic review. *Cancer* 1987;60:2727–2743.
 17. Lennon VA, Lambert EH, Leiby KR, Okarma TB, Taib S. Recombinant human acetylcholine receptor alpha-subunit induces chronic experimental autoimmune myasthenia gravis. *J Immunol.* 1991;146:2245–2248.
 18. Ackman JB, Kovacina B, Carter BW, Wu CC, Sharma A, Shepard JA et al (2013) Sex difference in normal thymic appearance in adults 20–30 years of age. *Radiology.* 268(1):245–53.
 19. Craven C, Reddy P. K., Steven P. R., Robert B. R. Effect of Corticosteroids on the Thymus in Myasthenia gravis. *Muscle & Nerve.* 1981; Sept/Oct: 425-8.